

## Human brain activation in response to olfactory stimulation by intravenous administration of odorants

Ai Miyanari<sup>a,d</sup>, Yoshiki Kaneoke<sup>a,c</sup>, Yasuki Noguchi<sup>a,c</sup>, Manabu Honda<sup>b,c</sup>,  
Norihiro Sadato<sup>b,c</sup>, Yasuyuki Sagara<sup>d</sup>, Ryusuke Kakigi<sup>a,c,e,\*</sup>

<sup>a</sup> Department of Integrative Physiology, National Institute for Physiological Sciences, Okazaki, Japan

<sup>b</sup> Department of Cerebral Research, National Institute for Physiological Sciences, Okazaki, Japan

<sup>c</sup> Department of Physiological Sciences, School of Life Sciences, The Graduate University for Advanced Studies, Kanagawa, Japan

<sup>d</sup> Graduate School of Agricultural and Life Sciences, The University of Tokyo, Tokyo, Japan

<sup>e</sup> RISTEX, JST, Tokyo, Japan

Received 2 December 2006; received in revised form 9 May 2007; accepted 1 June 2007

### Abstract

To identify the BOLD effects related to olfaction in humans, we recorded functional magnetic resonance imaging (fMRI) scans in response to intravenously instilled thiamine propyl disulfide (TPD) and thiamine tetrahydrofurfuryl disulfide monohydrochloride (TTFD). TPD and TTFD evoked a strong and weak odor sensation, respectively. Since we did not spray the odor stimuli directly, this method is expected to reduce the effect caused by direct stimulation of the trigeminal nerve. For the analysis of fMRI data, statistical parametric mapping (SPM2) was employed and the areas significantly activated during olfactory processing were located. Both strong and weak odorants induced brain activities mainly in the orbitofrontal gyrus (Brodmann's area: BA 11) in the left hemisphere. TPD (a strong odorant) induced activity in the subthalamic nucleus in the left hemisphere and the precentral gyrus (BA 6) and insula in the right hemisphere. TTFD (a weak odorant) induced activity in the superior frontal gyrus (BA 11) in the right hemisphere. In both circumstances, there was an increase in blood flow at the secondary olfactory cortex (SOC) but not the primary olfactory cortex (POC), probably due to a habituation effect in the POC. From the present results, we found brain activity in not only odor-specific regions but also regions whose levels of activity were changed by an intensity difference of odor stimuli.

© 2007 Elsevier Ireland Ltd. All rights reserved.

**Keywords:** Odor; Intensity; The primary olfactory cortex (POC); The secondary olfactory cortex (SOC); Human

The cortical areas responsible for olfactory perception were identified in animals with anatomical and electrophysiological methods [3,25]. In recent years neuroimaging techniques have allowed us to visualize odor-induced brain activation in humans [20,21,27] without dealing with the intensity.

In Japan, the intravenous olfaction test is widely used for the diagnosis of olfactory disorders [23]. After an intravenous administration of TPD (Alinamin<sup>®</sup>, Takeda Pharmaceutical Company Ltd., Osaka, Japan) and TTFD (Alinamin F<sup>®</sup>, Takeda Pharmaceutical Company Ltd., Osaka, Japan), subjects smell a garlic-like odor in their expired air. Since we do not spray the odorants directly, this method is expected to reduce the effect of

directly stimulating the trigeminal nerve. In addition, since TPD and TTFD induce a stronger and weaker odor sensation, respectively, we may be able to compare brain activations caused by each stimulus.

Twelve healthy right-handed male subjects (mean  $\pm$  S.D. age  $30.8 \pm 5.4$  years, range 27–42 years) with normal olfaction participated in this study. All subjects understood the experimental procedures and gave their written informed consent to participate in this experiment, which had been approved by the Ethical Committee of the National Institute for Physiological Sciences, Okazaki, Japan.

Stimulation was done with the intravenous infusion of TPD or TTFD. The subjects smelled a distinct garlic-like odor in their expired air after the infusion. TTFD evoked a weaker sensation than TPD owing to the substitution of the side chain of its odorous components. The order of TPD or TTFD infusion was randomized and counterbalanced across the subjects. We dissolved TPD and TTFD (2 ml) in physiological saline (50 ml)

\* Corresponding author at: Department of Integrative Physiology, National Institute for Physiological Sciences, Okazaki 444-8585, Japan.

Tel.: +81 564 55 7815; fax: +81 564 52 7913.

E-mail address: [kakigi@nips.ac.jp](mailto:kakigi@nips.ac.jp) (R. Kakigi).

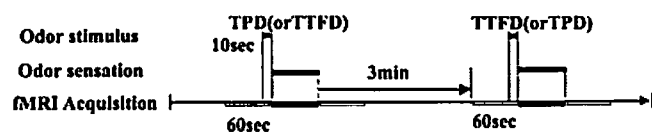


Fig. 1. Experimental time course: before the subjects perceived the odor, 60 s recordings were made. TPD or TTFD was instilled for 10 s. Six trials were measured in each subject at 3-min intervals after the subjects did not perceive any odorants.

and instilled them slowly into the left median cubital vein for 10 s. The subjects were instructed to press the button when the smell started and ceased. Physiological saline was instilled the same as TPD and TTFD as the state in which no odor was perceived.

Fig. 1 shows the experimental time courses. The experiments were controlled by Presentation software (Neurobehavioral Systems, Inc., San Francisco, CA). The subjects kept their eyes closed so as to avoid noticing the time of instillation. They wore masks with a tube for ventilation to keep the air clean in the measurement room. Six trials were measured in each subject at 3-min intervals after the subjects did not perceive any odorants.

After the experiment, all subjects evaluated the palatability for TPD and TTFD according to a five-grade system: (1) hate, (2) dislike, (3) neutral, (4) like and (5) strongly like. All subjects practiced nasal breathing at a constant rate before the experiment. During the experiment, to ascertain whether or not the subjects' breathing was constant throughout the experiment, their respirations were monitored with a nasal thermistor (respirator pickup TR-611T, Nihon Kohden, Japan).

A conventional block design was applied in this fMRI study. All data were collected on a three T MRI system (The Magnetom Allegra, Siemens Co., Erlangen, Germany) using a T2\*-weighted gradient-echo echo-planar imaging (EPI) sequence [repetition time (TR)/echo time (TE) = 2500 ms/30 ms, flip angle (FA) = 90°, slice thickness/gap = 3 mm/0 mm, field of view (FOV) = 192 mm × 192 mm, resolution = 3 mm × 3 mm, 40 slices]. In a single run, 94 volumes were obtained following two dummy images. To normalize individual brains into a standard brain, a three-dimensional (3D) T1-weighted image of each subject was collected using a magnetization-prepared rapid acquisition in gradient echo (MP-RAGE) sequence [15] [TR/TE = 2500 ms/4.38 ms, FA = 8, FOV = 230 mm × 230 mm, resolution = 0.9 mm × 0.9 mm].

The data analyses were implemented using statistical parametric mapping (SPM2; Wellcome Department of Cognitive Neurology, London, UK) [7,8] on MATLAB (Math Works, Sherborn, MA). Each individual brain was normalized to the standard brain space (Montreal Neurological Institute (MNI) brain template) [6] with re-sampling of 2 mm<sup>3</sup>. The parameters for affine and nonlinear transformation into the MNI template were estimated using the 3D T1-weighted image with least squares means [7,8]. Normalized data were then spatially smoothed with an isotropic Gaussian filter of 8 mm (full-width at half maximum, FWHM). A hemodynamic response function [9] as a general linear model was applied to smoothed data to identify the regions of the brain activated by the odor stimuli.

For investigation at the population level, individual data were then incorporated into a random effect analysis [10] with one sample *t*-test. The statistical threshold was set at  $P < 0.001$  (uncorrected for multiple comparisons). Regions activated by either or both TPD and TTFD (odorant-induced activation) were statistically determined by subtracting the activation with saline administration. Further, the first 6 s of the odor sensation block was analyzed to assess the effect of habituation. The MNI coordinates were converted into Talairach coordinates [24] using a nonlinear transformation algorithm formulated by Brett [4].

The subjects were instructed to press the button when the smell started and ceased. The onset time was  $90.1 \pm 11.9$  s (mean  $\pm$  S.D.) for TPD and  $96.1 \pm 11.9$  s for TTFD. The duration of smell was  $58.4 \pm 23.2$  s (mean  $\pm$  S.D.) for TPD and  $47.6 \pm 27.2$  s for TTFD. The paired *t* test did not reveal a significant difference in the mean of onset time ( $P = 0.929$ ) and the duration of smell ( $P = 0.704$ ) between TPD and TTFD.

The Chi-square test revealed that the strength of the odor differed significantly ( $P < 0.05$ ) but palatability did not. There was no significant difference in the mean respiration rate in each trial.

By the intravenous stimulation with TPD and TTFD, the subjects smelled a strong and weak odor in their expired air after the infusion (Table 1). The most activated region was observed in the orbitofrontal gyrus (Brodmann's area: BA 11) [ $x = -22, y = 48, z = -12$ ; Talairach coordinates] in the left hemisphere (Fig. 2). An increase in blood flow was observed at the SOC (Table 1). Although POC [ $x = 26, y = 43, z = -5$ ] was detected by the first 6 s analysis, but it was not significant.

TPD, which evoked a stronger sensation than TTFD, caused an increase in blood flow mainly at the frontal lobe, subthalamic nucleus, and insula. The area most activated was located in the subthalamic nucleus [ $x = -16, y = -8, z = -6$ ] in the left hemisphere. Significant brain activity was also found in the precentral gyrus (BA 6) [ $x = 30, y = -5, z = 48$ ] and insula [ $x = 34, y = 12, z = 16$ ] in the right hemisphere (Fig. 3). An increase in blood flow was observed at the SOC but not the POC (Table 1).

TTFD, which evoked a weaker sensation than TPD, induced an increase in blood flow at the superior frontal gyrus and cerebellum. The area most activated was in the superior frontal gyrus (BA 11) [ $x = 16, y = 56, z = -11$ ] in the right hemisphere (Fig. 4). TTFD induced significant activity in the SOC but not POC (Table 1).

The human POC seems to include the piriform, entorhinal cortex, and amygdala (BA 28, 34) [5] while the SOC includes the orbitofrontal cortex, insula, and striatum (BA 10, 11, 32, 47) [1,25]. Recently, neuroimaging techniques such as fMRI and PET have enabled us to locate primary and secondary cortices [20,21,27]. Several previous attempts to grasp brain activities in the POC using MRI showed that the increase in blood flow at the POC was small and inconsistent but activation of the SOC was large. It seems strange that activity in the POC was not clearly identified by neuroimaging, whereas other primary cortices such as visual [2], auditory [17] and somatosensory

Table 1  
Brain areas activated by odor stimuli (group analysis of 12 subjects,  $P < 0.001$ )

Area	BA	Hemisphere	x	y	z	z-Score
All						
Superior frontal gyrus	6	R	18	24	61	4.45
Orbitofrontal gyrus	11	L	-22	48	-12	6.65
TPD (strong stimulus)						
Subthalamic nucleus		L	-16	-8	-6	6.82
Insula		R	34	12	16	5.87
		R	40	6	11	5.45
		R	38	16	8	5.41
Precentral gyrus	6	R	30	-5	48	6.38
Middle frontal gyrus	8	R	24	25	41	4.98
	8	R	14	33	37	4.37
	9	L	-36	46	27	5.14
	10	L	-32	39	13	4.63
	10	R	36	47	7	4.48
Superior frontal gyrus	10	R	38	51	20	4.33
Middle temporal gyrus	37	L	-53	-66	5	5.35
TTFD (weak stimulus)						
Superior frontal gyrus	11	R	16	56	-11	6.95
Cerebellum		R	28	-63	-14	5.43
		R	22	-67	-11	5.21

Brain areas showing significant activation by intravenous odorant administration of TPD and TTFD: Statistical threshold was set at  $P < 0.001$  (uncorrected for multiple comparisons). The x, y, z coordinates are using the atlas of Talairach [24]. BA: Brodmann's area, L: left hemisphere, R: right hemisphere.

[19] cortices were comparatively easy to visualize. This can be due to habituation and desensitization. Rapid habituation in the piriform cortex (POC) was detected electrophysiologically in the rat [26], in which anterior piriform cortex neurons were habituated significantly faster than olfactory bulb neurons with both repeated and prolonged stimulation. Poellinger et al. [18], in a previous fMRI study, found that activity in the POC was weak or undetectable when dealing with a relatively long stimulation such as 30, 40, or 60 s. It is thus difficult to visualize activity in the POC, which could easily be habitu-

ated, due to the limits of time resolution of the MR scanner [18,21]. Our present study supports this view in that the first 6 s analysis detected the POC activation though it was not significant.

Sobel et al. [20] performed an experiment using a sniffing method in which subjects smell actively whether an odorant is present or absent, then reported the activation of the piriform and orbitofrontal cortex. It is known that the odorants in the expired breath are residual with a large amount present 10 min after an intravenous administration [13]. The mechanism

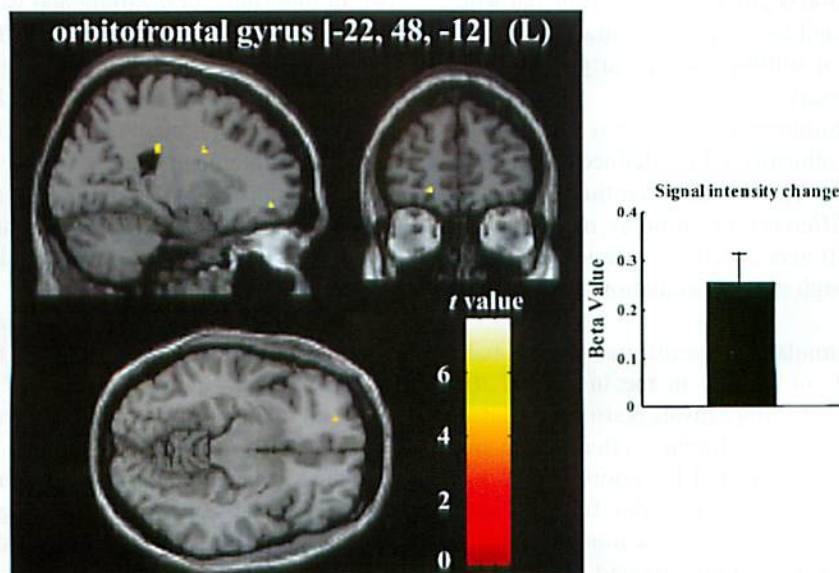


Fig. 2. Odorant-induced activation and signal intensity change: By the intravenous stimulation with TPD and TTFD, an increase in blood flow at the frontal lobe was induced. The area most activated was located in the orbitofrontal gyrus (BA 11) in the left hemisphere.

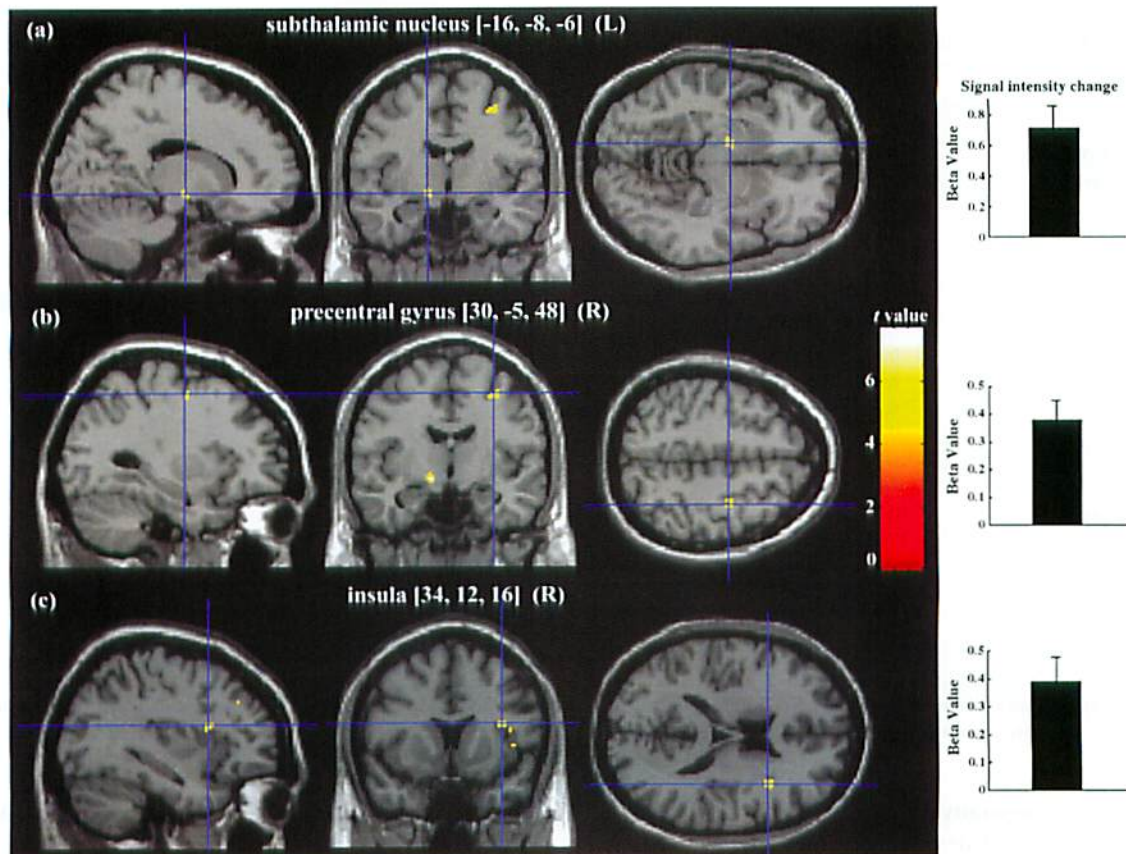


Fig. 3. TPD-induced activation and signal intensity change: The area most activated was located in the subthalamic nucleus in the left hemisphere (a). Furthermore, significant brain activity was also found in the precentral gyrus (BA 6) (b) and insula (c) in the right hemisphere.

of olfaction following an intravenous administration could be as follows: odorants incorporated into the blood reach the lung, then are excreted through expiration, then they stimulate the olfactory epithelium directly from the posterior nasal cavity. It is thought that an intravenous administration results in a long-duration stimulus and olfaction begins not with sniffing but with smelling using this method and for the primary olfactory cortex to be activated, the action of sniffing and an early time point before habituation are necessary.

The odorant-induced orbitofrontal activation is much more anterior than the "putative olfactory OFC" defined in a meta-analysis of imaging studies [11]. We think that this difference was mainly caused by a difference of stimulus methods and by a racial anatomical difference between Caucasians and Asians to some degree, though it is a speculation with no evidence.

Though the methods of stimulation have differed among studies, there have been reports of activity in the insula [17,20] following stimulation with odors. Since insula is strongly related to emotion as main regions of the limbic system, it seems plausible that these areas are activated by odors. The relationship of the subthalamic nucleus with odor function was reported [12]. The decrease in olfactory function in patients with Parkinson's disease (PD) is well investigated. While deep brain stimulation of the subthalamic nucleus had no effect on odor thresholds, in hyposmic PD patients, odor discrim-

ination was found to be significantly increased. Thus, the subthalamic nucleus may be involved in olfactory processing.

As for the precentral gyrus (BA 6), our previous MEG study showed activity there using the same method of stimulation [14]. In that study, both strong and weak odors induced event-related desynchronization (ERD) of the beta band (13–30 Hz) in the precentral gyrus, which might reflect the thalamo-cortical networks that enhance focal cortical activation through the simultaneous inhibition of other cortical areas [16]. Since MEG records physiological changes of cerebral cortex function, the obtained results by fMRI are usually not the same as those by MEG. However, since each method has its own advantages, it seems ideal that both MEG and fMRI are recorded for the same stimulation as we did.

Finally, the results that TPD-specific activated areas were mainly concentrated on the medial frontal gyrus (BA 8, 9) were interesting. Steinworth et al. [22] reported that odor is a central component of autobiographical memory, which allows us to travel mentally back in time. They examined the network supporting autobiographical memory, and then mentioned that it was a large network including the medial frontal cortex. Although they did not examine the effect of a difference in odorant intensity, our results raise the possibility that the medial frontal gyrus depends on odor intensity. Taken together, the results suggest that (1) the SOC is active regardless of odor

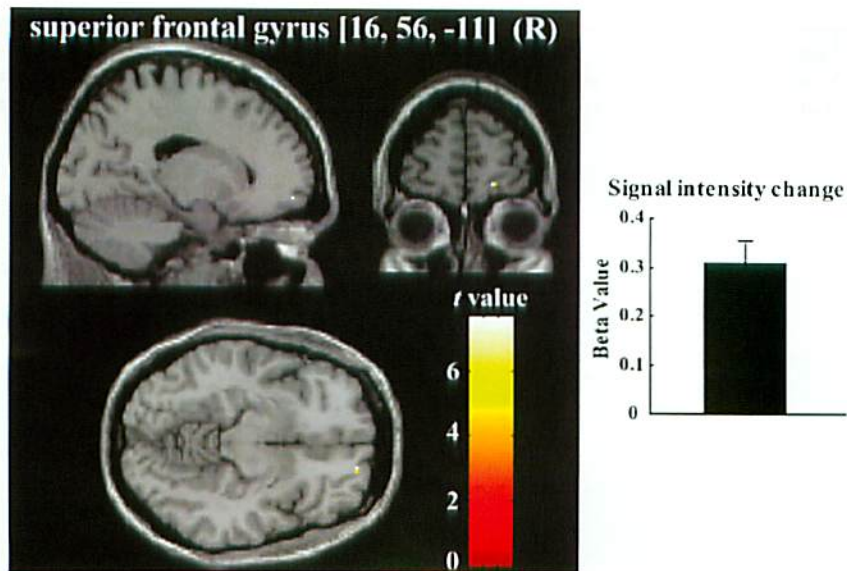


Fig. 4. TTFD-induced activation and signal intensity change: TTFD, which evoked a weaker sensation than TPD, induced the greatest increase in blood flow at the superior frontal gyrus (BA 11) in the right hemisphere.

intensity and (2) the cortical processing of strong and weak odor perception may be different.

#### Acknowledgements

This study was supported by the Japan Space Forum, Grant-in-Aid for Scientific Research on Priority Areas – Higher-Order Brain Functions – from The Ministry of Education, Culture, Sports, Science, and Technology, Japan.

#### References

- [1] A.C. Allison, The secondary olfactory areas in the human brain, *J. Anat.* 88 (1954) 481–488.
- [2] J.W. Belliveau, D.N. Kennedy Jr., R.C. McKinstry, B.R. Buchbinder, R.M. Weisskoff, M.S. Cohen, J.M. Vevea, T.J. Brady, B.R. Rosen, Functional mapping of the human visual cortex by magnetic resonance imaging, *Science* 254 (1991) 716–719.
- [3] S.L. Bressler, W.J. Freeman, Frequency analysis of olfactory system EEG in cat, rabbit, and rat, *Electroencephalogr. Clin. Neurophysiol.* 50 (1980) 19–24.
- [4] M. Brett, I.S. Johnsrude, A.M. Owen, The problem of functional localization in the human brain, *Nat. Rev. Neurosci.* 3 (2002) 243–249.
- [5] S.T. Carmichael, M.C. Clugnet, J.L. Price, Central olfactory connections in the macaque monkey, *J. Comp. Neurol.* 346 (1994) 403–434.
- [6] A.C. Evans, M. Kamber, D.L. Collins, D. MacDonald, *An MRI Based Probabilistic Atlas of Neuroanatomy: Magnetic Resonance Scanning and Epilepsy*, Plenum Press, New York, 1994, pp. 263–274.
- [7] K.J. Friston, A.P. Holmes, K.J. Worsley, J.B. Poline, C.D. Frith, R.S.J. Frackowiak, Statistical parametric maps in functional imaging: a general linear approach, *Hum. Brain Mapp.* 2 (1995) 189–210.
- [8] K.J. Friston, J. Ashburner, J.B. Poline, C.D. Frith, J.D. Heather, R.S.J. Frackowiak, Spatial registration and normalization of images, *Hum. Brain Mapp.* 3 (1995) 165–189.
- [9] K.J. Friston, P. Fletcher, O. Josephs, A. Holmes, M.D. Rugg, R. Turner, Event-related fMRI: characterizing differential responses, *Neuroimage* 7 (1998) 30–40.
- [10] K.J. Friston, A.P. Holmes, K.J. Worsley, How many subjects constitute a study? *Neuroimage* 10 (1999) 1–5.
- [11] J.A. Gottfried, D.H. Zald, On the scent of human olfactory orbitofrontal cortex: meta-analysis and comparison to non-human primates, *Brain Res. Brain Res. Rev.* 50 (2005) 287–304.
- [12] T. Hummel, U. Jahnke, U. Sommer, H. Reichmann, A. Müller, Olfactory function in patients with idiopathic Parkinson's disease: effects of deep brain stimulation in the subthalamic nucleus, *J. Neural Transm.* 112 (2005) 669–676.
- [13] R. Kazama, H. Zusho, A study on concentrations of odorous substance in intravenous olfaction test, *J. Otolaryngol. Jpn.* 84 (1980) 400–407 (in Japanese).
- [14] A. Miyanari, Y. Kaneoke, A. Ihara, S. Watanabe, Y. Osaki, T. Kubo, A. Kato, T. Yoshimine, Y. Sagara, R. Kakigi, Neuromagnetic changes of brain rhythm evoked by intravenous olfactory stimulation in humans, *Brain Topogr.* 18 (2006) 189–199.
- [15] J.P. Mugler, J.R. Brookeman, Three-dimensional magnetization-prepared rapid gradient-echo imaging (3D MP RAGE), *Magn. Reson. Med.* 15 (1990) 152–157.
- [16] C. Neuper, G. Pfurtscheller, Event-related dynamics of cortical rhythms: frequency-specific features and functional correlates, *Int. J. Psychophysiol.* 43 (2001) 41–58.
- [17] J. Plailly, A.J. Radnovich, M. Sabri, J.P. Royet, D.A. Kareken, Involvement of the left anterior insula and frontopolar gyrus in odor discrimination, *Hum. Brain Mapp.* 28 (2007) 363–372.
- [18] A. Poellinger, R. Thomas, P. Lio, A. Lee, N. Makris, B.R. Rosen, K.K. Kwong, Activation and habituation in olfaction—an fMRI study, *Neuroimage* 13 (2001) 547–560.
- [19] S.M. Rao, J.R. Binder, P.A. Bandettini, T.A. Hammeke, F.Z. Yetkin, A. Jesmanowicz, L.M. Lisk, G.L. Morris, W.M. Mueller, L.D. Estkowski, Functional magnetic resonance imaging of complex human movements, *Neurology* 43 (1993) 2311–2318.
- [20] N. Sobel, V. Prabhakaran, J. Desmond, G. Glover, R.L. Goode, E. Sullivan, J.D.E. Gabrieli, Sniffing and smelling: separate subsystem in the human olfactory cortex, *Nature* 392 (1998) 282–286.
- [21] N. Sobel, V. Prabhakaran, Z. Zhao, J.E. Desmond, G.H. Glover, E.V. Sullivan, J.D. Gabrieli, Time course of odorant-induced activation in the human primary olfactory cortex, *J. Neurophysiol.* 83 (2000) 537–551.
- [22] S. Steinvorth, S. Corkin, E. Halgren, Ecphory of autobiographical memories: an fMRI study of recent and remote memory retrieval, *Neuroimage* 30 (2006) 285–298.
- [23] S.F. Takagi, *Olfactory Tests: Human Olfaction*, University of Tokyo Press, Tokyo, 1989, pp. 35–69.

- [24] J. Talairach, P. Tournoux, *Co-planar Stereotaxic Atlas of the Human Brain*, Thieme Medical, New York, 1988.
- [25] T. Tanabe, H. Yarita, M. Iino, Y. Ooshima, S.F. Takagi, An olfactory projection area in orbitofrontal cortex of the monkey, *J. Neurophysiol.* 38 (1975) 1269–1283.
- [26] D.A. Wilson, Habituation of odor responses in the rat anterior piriform cortex, *J. Neurophysiol.* 79 (1998) 1425–1440.
- [27] R.J. Zatorre, M. Jones-Gotman, A.C. Evans, E. Meyer, Functional localization and lateralization of human olfactory cortex, *Nature* 360 (1992) 339–340.

